

### Distinguishing children's bites from adults' bites

Children often bite one another and they may also be bitten by animals. The challenge, therefore, is to recognise when an injury is a human bite and whether it was caused by an adult. If an adult bite is suspected, practitioners should always follow their organisation's safeguarding procedures by reporting their concerns to the designated person for child protection. A forensic dentist should also be consulted for an opinion as to whether the lesion is consistent with an adult or child, and whether there are characteristics to determine who bit the child. The British Association for Forensic Odontology have published guidelines about the gap between the eye teeth in the upper jaw that will distinguish adult from child bites, and this is a standard measurement that is made. However, this requires clinical expertise to interpret. There is no validation of these measurements in the literature. However, they are based on knowledge of normal dental anatomy – details can be found at: [www.bafo.org.uk](http://www.bafo.org.uk)

### Distinguishing human bites from animal bites

Dogs and other carnivores (eg, ferrets or rats) tend to tear the skin and leave deep puncture wounds. These are also much narrower bites than human ones.

### What should a paediatrician do if they suspect a child has sustained a human bite?

Any human bite could be abusive and should be fully assessed, ideally by a forensic dentist (see [www.bafo.co.uk](http://www.bafo.co.uk)). Forensic dentists potentially play an important part in the child protection process. If involved early enough, they can take serial photographs and casts of the bite, and possibly retrieve DNA, which can help identify the perpetrator. However, there are fewer than 30 in the UK.

If a doctor or dentist is unable to make immediate contact with a forensic dentist, they should first measure and record the intercanine distance, then obtain photographs of the suspected bite. The photographic record must include one plain image and a second image that includes a right-angled measuring device beside the mark. If the bite is on a curved surface – eg, the arm – then the image with the measuring device should be recorded in each plane. A forensic dentist should then be consulted. Washing around the area of the bite should be avoided as it may be possible to obtain the perpetrator's DNA from the injury. If there is going to be a delay in getting a specialist opinion, it may be valuable to repeat the photographs after one or two days, as with less swelling the individual marks from each tooth may be clearer.

Registered charity numbers 216401 and SC037717. Photography by Paul Close. Posing by models. Stores code NS/1088

This leaflet is based on the work of the Welsh Child Protection Systematic Review group, which is engaged in a rolling programme of systematic reviews of published research literature on aspects of physical child abuse.

The information is based on the review published in June 2007. This is a collaborative project between the Department of Child Health at Cardiff University and the NSPCC.

Information about this and the project's other systematic reviews can be found at the CORE-INFO website: [www.core-info.cardiff.ac.uk](http://www.core-info.cardiff.ac.uk)

If you are worried about a child who is at risk of abuse or in need of help, or if you are a child in need of support, the NSPCC Child Protection Helpline is available 24 hours a day, seven days a week.

- Call 0808 800 5000 to speak to a Helpline adviser.
- If you are deaf or hard of hearing, you can call the Helpline's textphone service on 0800 056 0566. **0800 056 0566**
- A bilingual Welsh/English Helpline is also available on 0808 100 2524. **0808 100 2524**
- An Asian Helpline is available in
  - Bengali/Sylehti **0800 096 7714**
  - Gujarati **0800 096 7715**
  - Hindi **0800 096 7716**
  - Punjabi **0800 096 7717**
  - Urdu **0800 096 7718**

You can order up to five free copies of this leaflet by sending an A5 self-addressed envelope, plus £1.30 in stamps, to NSPCC Publications. For more than five copies the price is 20p per leaflet including postage and packing.

### NSPCC Publications

Weston House, 42 Curtain Road, London, EC2A 3NH  
Tel: 020 7825 7422 Fax: 020 7825 2763  
You can order online at [www.nspcc.org.uk/inform](http://www.nspcc.org.uk/inform)

The leaflet can also be downloaded from NSPCC inform [www.nspcc.org.uk/inform](http://www.nspcc.org.uk/inform)

**NSPCC**   
**CHILD PROTECTION  
HELPLINE**  
**0808 800 5000**

**CORE-INFO**   
Welsh Child Protection Systematic Review Group

**NSPCC**   
Cruelty to children must stop. FULL STOP.

**CORE-INFO:**  
**Oral injuries  
and bites on children**



This leaflet summarises what is currently known about oral injuries and human bites in relation to child abuse. The information will be of particular interest to dentists, dental care professionals, paediatricians, and A & E staff. The leaflet will also be relevant to nursery nurses, health visitors, school nurses, teachers, legal practitioners, social workers and the police. It is based on systematic reviews of all the quality work in the world literature about oral injuries and bites on children; full details are available at: [www.core-info.cardiff.ac.uk](http://www.core-info.cardiff.ac.uk)

## Oral injuries

### What do we know about injuries to the mouth?

Up to 50 per cent of children sustain an injury to the mouth by the time they leave school. Most of these are accidental and, in older children, often caused by falls and sporting accidents. In cases of physical abuse, the head and face are the areas of the body most commonly injured. Injuries to the lips are the commonest recorded abusive injury to the mouth. These are either cuts or bruises. However, all areas of the mouth can be injured in physical abuse: teeth may be displaced or broken and there may be cuts, abrasions or bruises to the inside of the lips, the roof of the mouth, the tongue or the lingual frenum (underneath the tongue). Injuries to the mouth, including the teeth, can cause considerable pain and discomfort and, if left untreated, may well affect a child's appetite and growth.

### How can you tell there has been an injury to the mouth?

Unless you are a dentist it is very difficult to tell. However, a child may complain of a pain in their mouth or have difficulty eating, or you may notice that the teeth are discoloured (brown or grey), which may mean that there is

an old injury. A broken tooth may be recognised only because of a subtle grey discolouration. Abusive injuries to the mouth are not always obvious and, unless a child discloses abuse, will come to light only if you notice that permanent teeth are inexplicably missing.

### Is a torn labial frenum diagnostic of physical child abuse?

The labial frenum is the fold of tissue inside the mouth that joins the upper or lower lip to the gums. For a long time practitioners have believed that injury to the upper labial frenum is diagnostic of physical abuse.

In the scientific literature there are fewer than 50 recorded cases of an abusive torn labial frenum in children. The vast majority of these children suffered from multiple injuries and died from the assault. Most were under five years old. However, a torn frenum can also occur accidentally if a toddler or young child falls on their face, catches their mouth on low-level furniture or receives an accidental blow to the face – eg, by a swing.

There is not enough evidence in the literature to support the view that a torn labial frenum in isolation is diagnostic of child abuse. Any injury of this type must be assessed in the context of the explanation given, the child's developmental stage, a full examination and other relevant investigations as appropriate.

### What should a dental professional do if they suspect a child has been abused?

The General Dental Council (GDC) makes it absolutely clear that dental professionals, in common with all those who work with children, have a responsibility to know the local child protection procedures and to follow them if they suspect a child may be at risk because of abuse or neglect. Further information and guidance about the responsibilities of dentists has been published in a handbook, *Child Protection and the Dental Team: an introduction to safeguarding children in dental practice*. This educational resource is available at: [www.cpd.org.uk](http://www.cpd.org.uk)

### What should a paediatrician do if they suspect a child has been abused?

If a paediatrician suspects a child of being abused, a routine examination of the child's mouth and teeth should always be carried out. Paediatricians therefore need an understanding of the basic dentition of children at different ages and stages of development, and should seek a dental opinion if there are concerns.

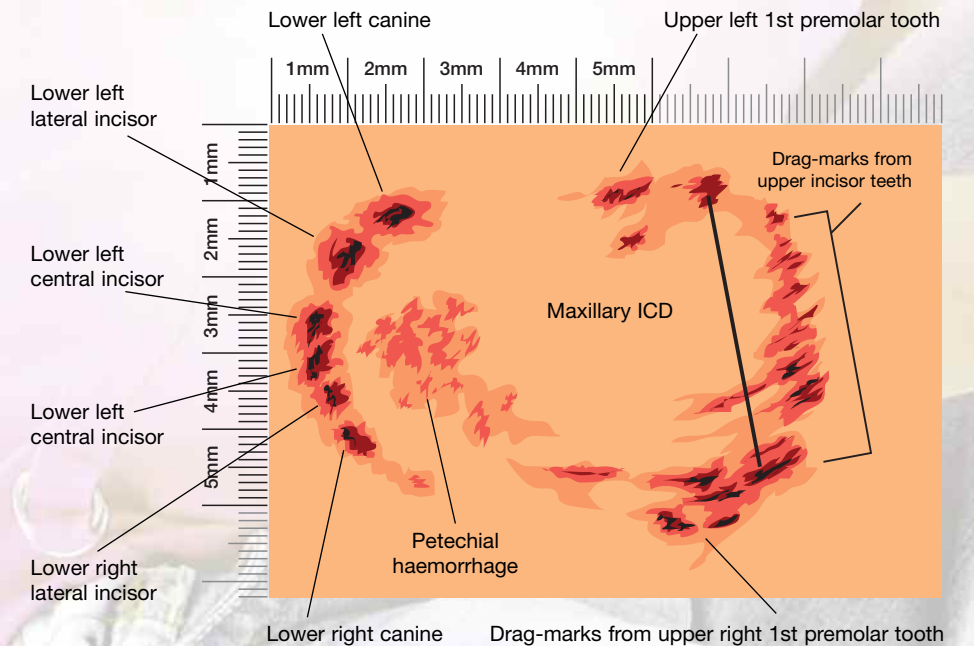
## Bites

### How common are injuries caused by bites?

Bites are a relatively common injury in children. Approximately one per cent of all A & E attendances are due to bites, and around one in 600 children attending A & E have been bitten. When an adult bites a child sufficiently hard to leave a mark, it is an assault. An adult bite on a child is the only physical injury where there is the potential to identify exactly who has attacked the child.

### What do injuries caused by bites look like?

A bite leaves an oval or circular mark, consisting of two symmetrical, opposing, u-shaped arches separated at their base by an open space. The arcs may include puncture wounds, indentations or bruising from the marks of individual teeth. These marks are what make bites unique.



A bite may be confused with other skin disorders – eg, ringworm, drug reaction, *pityriasis rosea*. However, there is no scaling of the skin in a bite, as there is in some of these conditions, and most skin disorders will be spread over the body or have other symptoms associated with them.