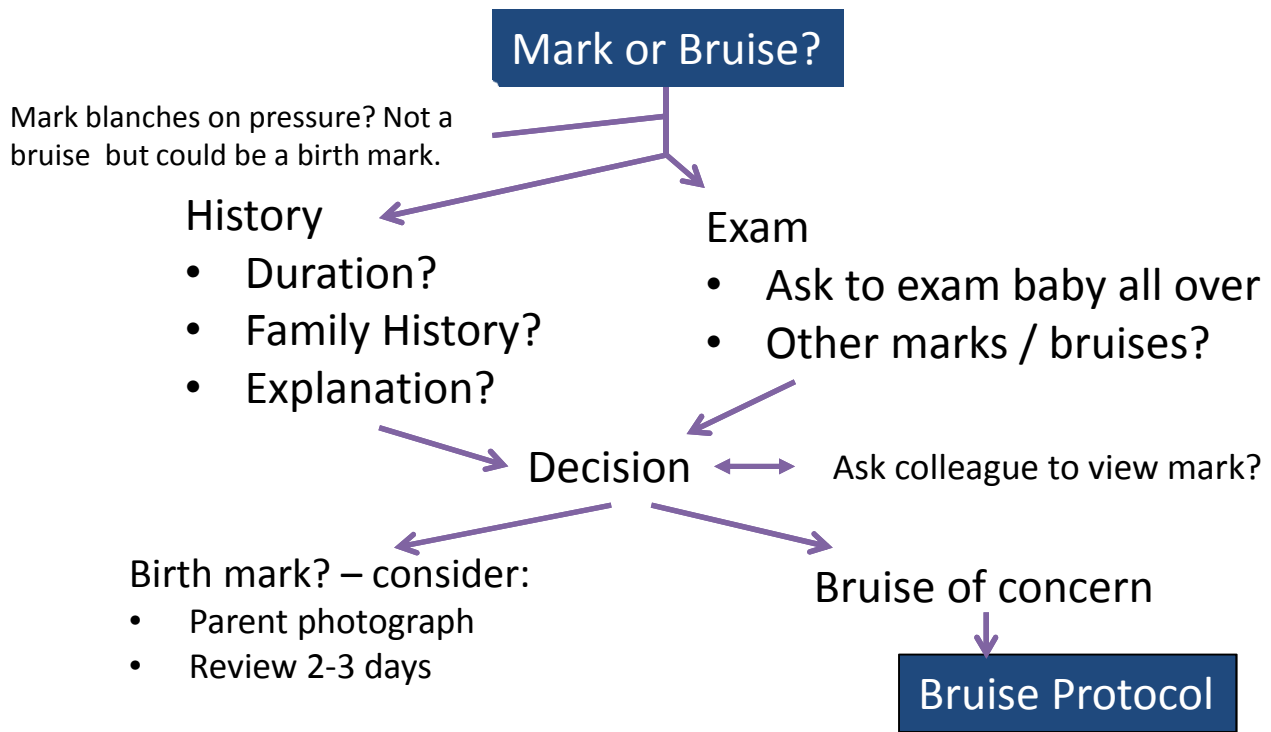


Assessment of Marks in Babies and Children

Prelude to Unexplained and Suspicious Injury (Bruise) Protocol

Advice for front-line health professionals



Comments

- Mark present from birth or early life and persists – probably birth mark. Observe if necessary.
- Mark in suspicious area, around mouth or eyes, on ear + Parent agrees is bruise or you think is a bruise:
- Infant with nose bleed, mouth bleed: (History: e.g. “blood spurted out” = high concern.)
- Skin blister in newborn / infant: probably staph infection.
- Infant unwell or injured in any way:

Points to observe:

1. Mongolian blue spots are purple, present in sacral area + satellite spots.
2. No general welfare concerns + looks like birth mark: safe to review.
3. In most cases of inflicted “precursor” bruise, parents usually concede mark is a bruise but the explanation suggests unreasonable force, e.g. held while feeding, or is implausible, e.g. lying on dummy. This is where the Core Info advice is useful.

Hospital